

CASE REPORT

Exudative Retinal Detachment and Macular Hole as a Rare Sequelae of Central Vein Occlusion

RATHNA R¹, MUSHAWIAHTI M¹, BASTION MLC¹, MASDAR A²,
ROPILAH AR¹

¹Department of Ophthalmology, ²Department of Anesthesiology, Faculty of Medicine, Universiti Kebangsaan Malaysia Medical Centre, Jalan Yaacob Latif, Bandar Tun Razak, 56000 Cheras, Kuala Lumpur, Malaysia.

ABSTRAK

Oklusi vena retina adalah sesuatu yang jarang berlaku dalam usia muda. Ia biasanya kurang berbahaya dan mempunyai prognosis yang baik di kalangan pesakit muda. Edema makula adalah salah satu komplikasi penyakit ini yang memerlukan rawatan dengan suntikan mata 'anti vascular endothelial growth factor'. Selain itu pesakit oklusi vena retina ini juga boleh mengalami komplikasi seperti pendarahan dalam mata dan glaukoma. Kami melaporkan kes oklusi vena retina pada seorang wanita muda yang datang kepada kami dengan aduan kabur penglihatan pada mata kiri selama empat bulan. Pemeriksaan mata menunjukkan optik disk hiperemik, saluran vena bengkak, pendarahan dalam saraf mata, edema makula dan retina lekang. Sebulan selepas menerima suntikan ranibizumab untuk makula edema, pesakit mengalami makula berlubang. Selepas empat bulan saraf berlubang telah tertutup dengan spontan tetapi masih terdapat bengkak pada bahagian makula. Komplikasi jarang seperti saraf lekang dan makula berlubang jika dikesan awal mungkin boleh diberi rawatan yang bersesuaian untuk memelihara penglihatan yang baik.

Kata kunci: makula berlubang, makula bengkak, suntikan ranibizumab, oklusi vena retina

ABSTRACT

Central retinal vein occlusion (CRVO) is uncommon among young patients. Among the young adults, CRVO tends to be more benign with good visual prognosis. Macular oedema secondary to retinal vein occlusion is a relatively common complication that is currently being treated with intravitreal anti vascular endothelial growth factor with good outcomes. Other complications include lamellar hole,

Address for correspondence and reprint requests: Mushawiahti M. Department of Ophthalmology, Faculty of Medicine, Universiti Kebangsaan Malaysia Medical Centre, Jalan Yaacob Latif, Bandar Tun Razak, 56000 Cheras, Kuala Lumpur, Malaysia. Tel: +603 91455981 E-mail: drmusha@gmail.com.

vitreous hemorrhage and neovascular glaucoma. We report a case of central retinal vein occlusion in a young female who presented to us with the complaint of blurring of vision in the left eye for four months. Fundus examination showed hyperemic optic disc, dilated tortuous vein, extensive retinal hemorrhages with macular oedema and an inferior shallow exudative retinal detachment. One month later, intravitreal ranibizumab injection for her macular oedema, a full thickness macular hole developed with reduction of macular oedema. Four months later, the hole spontaneously closed but her macular oedema persisted. The possibility of rare complications like exudative retinal detachment and full thickness macular hole must be kept in mind to ensure early detection and effective management is provided to preserve vision.

Keywords: macular hole, macular oedema, ranibizumab, retinal vein occlusion

INTRODUCTION

Central retinal vein occlusion (CRVO) constitutes the second most common cause of retinal vascular disease after diabetic retinopathy and it is a vital cause of visual impairment (Keane & Sadda 2011). It is often seen as disease of the elderly population. CRVO is associated with arteriosclerotic or atherogenic disease, glaucoma or factors which affects blood coagulability and viscosity (Walters & Spalton 1990).

Macular oedema is the most common sight threatening complication of CRVO (Prajapati et al. 2014). Patients may also develop complications such as lamellar hole, vitreous hemorrhage and neovascular glaucoma secondary to CRVO (Yau et al. 2008).

We report an unusual case of a young patient with CRVO who developed rare complication of exudative retinal detachment (ERD) and full thickness macular hole (FTMH) that closed spontaneously.

CASE REPORT

A 39-year-old lady with underlying diabetes mellitus, hypertension and hyperlipidemia presented to the eye clinic with blurring of vision in the left eye for four months. Best corrected visual acuity was 6/9 in the right eye and 1/60 in the affected eye. Anterior segment examination was unremarkable with normal intraocular pressure. Fundus examination of the left eye revealed hyperemic optic disc, dilated tortuous vein, extensive retinal hemorrhages with macular oedema and an inferior shallow exudative retinal detachment (Figure 1). Optical coherence tomography (OCT) showed macular oedema with presence of subretinal fluid (Figure 2). The central retinal thickness was extremely thick 526 μm (Normal central thickness should be 250 or less). Fundus fluorescein angiography (FFA) imaging revealed delayed arteriovenous transit time with capillary and venous dilation which confirmed the diagnosis of vein occlusion. FFA also showed multiple

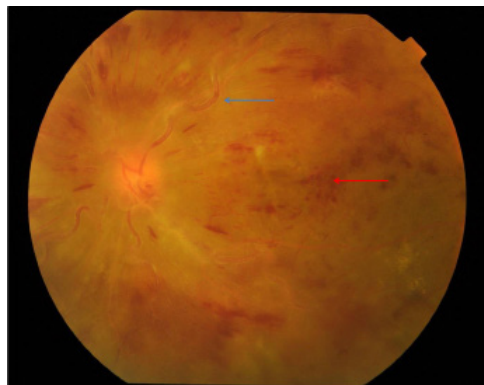


Figure 1: Fundus photography at presentation showing dilated tortuous vessels (blue arrow) and extensive retinal hemorrhage (red arrow).

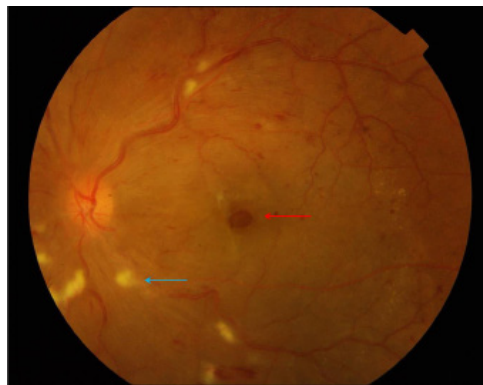

Figure 3: Fundus photograph after first intravitreal ranibizumab showing formation macular hole (red arrow) with presences of retinal hemorrhages and cotton wool spots (blue arrow).

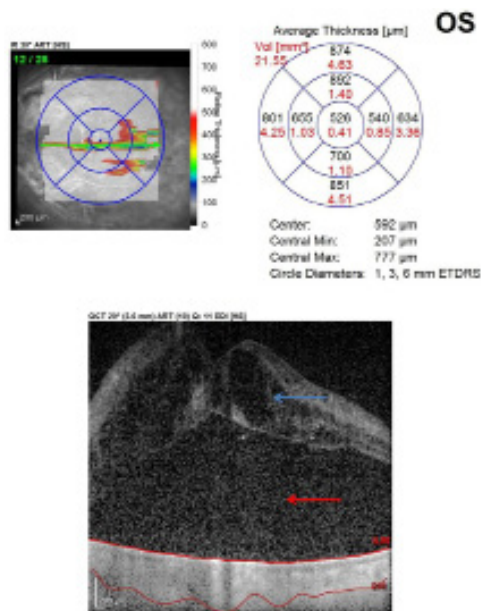


Figure 2: OCT macular at presentation showing cystoids macular oedema (blue arrow) with subretinal fluid (red arrow).

areas of capillary non perfusion about seven disc diameters and leaking of fluorescein in the macular area which denoted the presence of macular oedema. Thus, our impression was left ischaemic CRVO in view of patient’s poor vision, extensive intraretinal

hemorrhages at all four quadrants and multiple areas of non-perfusion in FFA. Patient was treated with intravitreal ranibizumab 0.5 mg for her macular oedema and full pan retinal photocoagulation was given in view of the ischaemic changes. However, at one month follow-up there was still no visual or clinical improvement. The anterior segment examination was normal with no rubeosis iridis or new vessels at the angles seen. Intraocular pressure was normal. Fundus examination showed slight decrease number of intraretinal hemorrhages and presence of cotton wool spot (Figure 3). Fundus had no retinal neovascularization. The OCT showed formation of full thickness macular hole with decreasing macularoedema (Figure 4). Patient continued receiving four more doses of intravitreal ranibizumab injection given monthly as per suggested protocol. After four months, the full thickness macular hole closed spontaneously and her exudative retinal detachment resolved

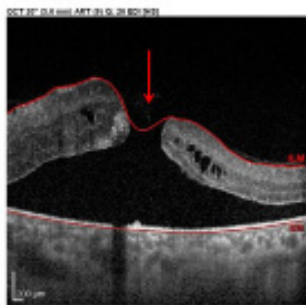
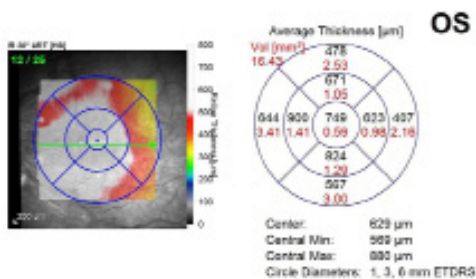


Figure 4: OCT macular after first intravitreal ranibizumab showing stage three full thickness (arrow) macular hole with presence of macular oedema and subretinal fluid.

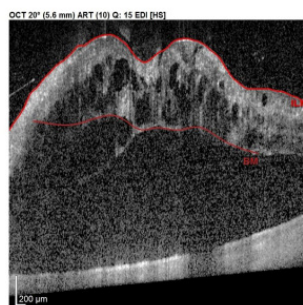
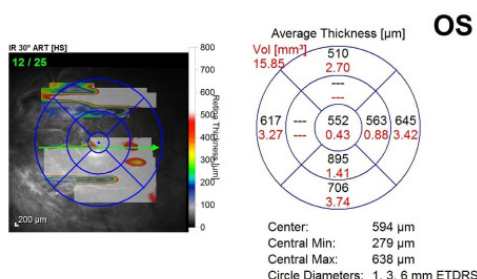


Figure 6: OCT macular after four months showing spontaneous closure of full thickness macular hole with posterior vitreous detachment, presence of macular oedema and subretinal fluid.

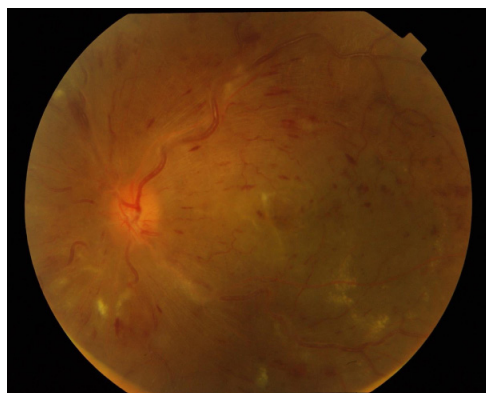

Figure 5: Fundus photography after four months showing dilated tortuous vessels with the presences of retinal hemorrhages and cotton wool spots.

but intraretinal hemorrhages and cotton wool spots were still present (Figure 5). OCT showed macular oedema with large subretinal fluid still persistent and her vision further deteriorated to counting finger (Figure

6). We then decided to suspend any further intervention due to her poor visual prognosis caused by the underlying macular ischaemia.

DISCUSSION

Central retinal vein occlusion is usually seen in the elderly patients aged over 50 years and it is usually associated with systemic conditions such as hypertension and atherosclerotic heart disease, glaucoma and abnormalities of clotting mechanism or blood viscosity (Walters & Spalton 1990). CRVO is considered rare in the younger age group of less than 40 years. Many previous reviews have showed the percentage of young patients affected with CRVO ranges only from 8 to 15% (Giuffré et al. 1992; Walters & Spalton

1990).

There are two types of CRVO that were described i.e. milder non-ischaemic variant and the more severe ischaemic variant. The non-ischaemic CRVO is characterized by minimal degree of capillary non-perfusion while the ischaemic type has extensive capillary nonperfusion with guarded visual prognosis (Fong & Schatz 1993). CRVO in young adult were frequently reported as the non ischaemic type and it is usually associated with good visual prognosis (Giuffré et al. 1992; Ichioka et al. 1985; Magargal et al. 1981. Walters & Spalton 1990). On the other hand in our case, this young patient had ischaemic CRVO with a downhill course which was probably due to her underlying poorly controlled hypertension and diabetes mellitus. Similarly, Gupta et al. (1993), found 8 out of the 25 young patients suffering from ischaemic CRVO with poor visual outcome while a series by Priluck et al. (1980) observed ischaemic CRVO in half of their 42 patients aged 40 years or less.

Ischaemic CRVO has a rapid onset venous obstruction which results in retinal hypoperfusion, capillary closure and hypoxia (Walters et al. 1990). This causes the release of vascular endothelial growth factor (VEGF) and inflammatory mediators which commonly leads to complications such macular oedema with lamellar hole, vitreous hemorrhage, optic atrophy, and neovascular glaucoma (Walters & Spalton 1990).

In our case report, besides macular oedema which is a common complication of CRVO, patient

also developed exudative retinal detachment and full thickness macular hole. Exudative retinal detachment (ERD) is an uncommon complication of retinal vein occlusion which typically characteristically develops in ischaemic cases and is associated with poor visual prognosis (Ravalico et al. 1992; Schatz et al. 1976; Weinberg et al. 1990) reported eight cases of ERD following branch retinal vein occlusion (BRVO) while Weinberg et al. (1990) presented four cases of ERD resulting from CRVO.

The pathogenesis of ERD depends on many factors which includes leakage from damaged vasculature, impaired absorbing function of retinal capillaries and retinal pigment epithelium pump. Increased hydrostatic pressure and absence of retinal venous collaterals may also lead to the formation of ERD (Ferencz et al. 2007; Schatz et al. 1976; Weinberg et al. 1990). In our case, most likely the severe retinal ischaemia led to the release of VEGF and other chemical mediators into the vitreous. These mediators caused an increased vascular permeability leading to extensive exudation from the retinal vessels. Along with an impaired retinal capillary absorbing function and damaged retinal epithelium pump, it led to the formation of exudative retinal detachment. The ERD that had resolved during subsequent visits was probably due to pan retinal photocoagulation that was given, causing disruption of the retinal pigment epithelium thus allowing absorption of subretinal fluid and obstruction of the leaking capillaries.

Full thickness macula hole (FTMH)

is another rare complication of CRVO. In this particular case, FTMH developed during the early phase of the disease after the first injection of intravitreal ranibizumab. Nagpal et al. (2011), reported FTMH formation after intravitreal bevacizumab injection in a patient with hemi-central retinal vein occlusion which was probably due to acute development of posterior vitreous detachment. Muramatsu et al. (2015), proposed macular hole in a patient with branch vein occlusion after intravitreal ranibizumab was due to acute regression of macular oedema and increased fibrosis after the anti VEGF therapy which may have triggered a mechanical force to damage the retina, thus possibly causing macular hole formation. The mechanism of macular hole in our case was probably due to the rapid reduction in the macular oedema after anti-VEGF therapy together with vitreomacular traction leading to the formation of FTMH.

During the course of treatment, the FTMH had spontaneous closure after the fourth intravitreal ranibizumab injection. The spontaneous closure of FTMH in this patient was probably due to the posterior vitreous detachment leading to a release of traction and subsequent glial proliferation bridging the gap between the macular hole.

Despite monthly intravitreal ranibizumab injection as suggested by major studies, the macular oedema and subretinal fluid persisted in our patient with worsening of vision (Brown et al. 2010). Refractory macular oedema regardless of treatment may occur in some cases which may be due to either

presence of vitreomacular traction or resistance to treatment with anti VEGF itself. The OCT finding of posterior vitreous detachment stage two in our case excludes vitreomacular traction as a cause of persistent macular oedema. Thus, the possible cause for the refractory macular oedema in this case was due to the resistance to the anti-VEGF agent. Therefore, the need for starting intravitreal steroid may be considered in this kind of cases.

The use of intravitreal steroid was proposed in the SCORE study which utilized triamcinolone for macula edema in CRVO. However, its usage has been associated with high rate of elevated intraocular pressure. While a study done by Sharareh et al. (2013), reported that a subset of their study patients who did not have resolution of macular oedema with anti-VEGF treatment, responded to intravitreal dexamethasone implant. Similarly, a study done by Wallsh et al. (2016) and Manousaridis et al. (2017) demonstrated an improvement in retinal morphology and macular function after intravitreal dexamethasone implant with lower rate of complication such as high intraocular pressure and cataract progression.

However, in our case, in spite of persistent macular oedema and large subretinal fluid the decision to suspend further treatment was made due to poor visual prognosis caused by underlying macular ischaemia evidenced by worsening of patient's vision, extensive intraretinal hemorrhages and cotton wool spots.

CONCLUSION

CRVO is a common cause of sudden and severe visual impairment. Its occurrence in younger people is uncommon. Many reports also suggest that CRVO in young patients are commonly non-ischaemic type with good visual prognosis. However, we presented a case report regarding a young patient with ischaemic CRVO. Her case was further complicated with presence of persistent macular oedema which was refractory to anti VEGF therapy. She also had two other rare complications of CRVO which included FTMH and ERD. Therefore, early detection and effective management important to preserve vision and prevent serious complications.

ACKNOWLEDGEMENT

The authors thank Mr. Hairul Nizam Harun for image editing.

REFERENCES

- Brown, D.M., Campochiaro, P.A., Singh, R.P., Li, Z., Gray, S., Saroj, N., Rundle, A.C., Rubio, R.G., Murahashi, W.Y., CRUISE Investigators. 2010. Ranibizumab for macular edema following central retinal vein occlusion: six-month primary end point results of a phase III study. *Ophthalmology* **117**(6): 1124-33. e1.
- Ferencz, J.R., Rosen, E., Tam, G., Gilady, G., Rubowich, A., Assia, E.I., Korzets, Z. 2007. Treatment of total exudative retinal detachment due to central retinal vein occlusion by intravitreal bevacizumab in a patient with p-ANCA vasculitis. *Clin Ophthalmol* **1**(3): 347-51.
- Fong, A.C., Schatz, H. 1993. Central retinal vein occlusion in young adults. *Surv Ophthalmol* **37**(6): 393-417.
- Giuffrè, G., Randazzo-Papa, G., Palumbo, C. 1992. Central retinal vein occlusion in young people. *Doc Ophthalmol* **80**(2): 127-32.
- Gupta, A., Agarwal, A., Bansal, R.K., Agarwal, A., Chugh, K.S. 1993. Ischaemic central retinal vein occlusion in the young. *Eye (Lond)* **7**(Pt 1): 138-42.
- Ichioka, H., Ueno, S., Ishigoka, H., Yasubuchi, Y., Asayama, K. 1985. Central retinal vein occlusion in young adults. *Nippon Ganka Gakkai Zasshi* **89**(7): 826-31.
- Keane, P.A., Sadda, S.R. 2011. Retinal vein occlusion and macular edema - critical evaluation of the clinical value of ranibizumab. *Clin Ophthalmol* **5**: 771-81.
- Magargal, L.E., Brown, G.C., Augsburger, J.J., Parrish, R.K. 1981. Neovascular glaucoma following central retinal vein obstruction. *Ophthalmology* **88**(11): 1095-101.
- Manousaridis, K., Peter, S., Menzel, S. 2017. Outcome of intravitreal dexamethasone implant for the treatment of ranibizumab-resistant macular edema secondary to retinal vein occlusion. *Int Ophthalmol* **37**(1): 47-53.
- Muramatsu, D., Mitsuhashi, R., Iwasaki, T., Goto, H., Miura, M. 2015. Macular hole formation following intravitreal injection of ranibizumab for branch retinal vein occlusion: a case report. *BMC Res Notes* **8**: 358.
- Nagpal, M., Mehta, V., Nagpal, K. 2011. Macular hole progression after intravitreal bevacizumab for hemicentral retinal vein occlusion. *Case Rep Ophthalmol Med* **2011**: 679751.
- Prajapati, V.A., Vasavada, D., Patel, S.M., Chauhan, W., Prajapati, V. 2014. A study of evaluation of various risk factors of retinal vein occlusion. *International Journal of Research in Medical Sciences* **2**(3): 1054-7.
- Priluck, I.A., Roberstson, D.M., Hollenhorst, R.W., 1980. Long term follow up of occlusion of central vein in young adults. *American Journal of Ophthalmology* **90**(2): 190-197, 199-202.
- Ravalico, G., Battaglia Parodi, M. 1992. Exudative retinal detachment subsequent to retinal vein occlusion. *Ophthalmologica* **205**(2): 77-82.
- Schatz, H., Yannuzzi, L., Stransky, T.J. 1976. Retinal detachment secondary to branch vein occlusion: Part II. *Ann Ophthalmol* **8**(12): 1461-71.
- Sharareh, B., Gallemore, R., Taban, M., Onishi, S., Wallsh, J. 2013. Recalcitrant macular edema after intravitreal bevacizumab is responsive to an intravitreal dexamethasone implant in retinal vein occlusion. *Retina* **33**(6): 1227-31.
- Wallsh, J., Sharareh, B., Gallemore, R. 2016. Therapeutic effect of dexamethasone implant in retinal vein occlusions resistant to anti-VEGF therapy. *Clin Ophthalmol* **10**: 947-54.
- Walters, R.F., Spalton, D.J. 1990. Central retinal vein occlusion in people aged 40 years or less: a review of 17 patients. *Br J Ophthalmol* **74**(1):

30-5.

Weinberg, D., Jampol, L.M., Schatz, H., Brady, K.D. 1990. Exudative retinal detachment following central and hemicentral retinal vein occlusions. *Arch Ophthalmol* **108**(2): 271-5.

Yau, J.W., Lee, P., Wong, T.Y., Best, J., Jenkins, A. 2008. Retinal vein occlusion: an approach to diagnosis, systemic risk factors and management. *Intern Med J* **38**(12): 904-10.

Received: 31 Jul 2017

Accepted: 13 Nov 2017