

## CASE REPORT

## Locked-in Syndrome Following a King Cobra (*Ophiophagus hannah*) Envenomation

AHMAD KHALDUN I<sup>1</sup>, MOHD FYZAL B<sup>2</sup>, SOO CI<sup>2</sup>, YEAP BT<sup>3</sup>,  
MOHAMED FAISAL AH<sup>2</sup>

<sup>1</sup>Department of Emergency Medicine, <sup>2</sup>Department of Medicine, Faculty of Medicine, Universiti Kebangsaan Malaysia Medical Centre, Jalan Yaacob Latif, Bandar Tun Razak, 56000 Cheras, Kuala Lumpur, Malaysia.

<sup>3</sup>Faculty of Medicine and Health Sciences, Universiti Malaysia Sabah, Jalan UMS, 88999 Kota Kinabalu Sabah, Malaysia.

### ABSTRAK

Gigitan dan gejala bisa dari ular Tedung Selar, *Ophiophagus hannah* melibatkan manusia adalah agak jarang berlaku. Bisa ular bertindak di bahagian pra-simpangan saraf motor yang menyebabkan kelumpuhan otot. Sindrom terkunci atau "locked-in" adalah gejala klinikal dimana pesakit tidak berupaya untuk bergerak walaupun masih sedar. Sindrom neurotoksik akibat dari gigitan ular tedung selar ini menyerupai pesakit yang kematian otak. Kami melaporkan kes seorang lelaki pertengahan umur dengan defisit neurologi yang progresif berikutan gigitan ular Tedung Selar di lengan kanannya. Beliau menunjukkan gejala klinikal bisa neurotoksik setempat dan sistemik. Berikutan keadaan klinikal yang semakin parah, beliau telah diintubasi dan di sambungkan kepada alat bantuan pernafasan di jabatan kecemasan. Beliau menerima sejumlah 33 vial antibisa monospesifik *Ophiophagus hannah* dan seterusnya pulih dengan baik tanpa menunjukkan sebarang defisit neurologi. Secara retrospektifnya, beliau dapat mendengar dan mengingati pebuatan orang di sekeliling dan kesakitan semasa terbaring lumpuh di unit rawatan rapi. Beliau menyifatkan ianya sebagai satu pengalaman yang amat menakutkan dan menyakitkan. Kes klinikal sindrom "locked-in" akibat dari gejala bisa sistemik ular Tedung Selar amat jarang dilaporkan. Adalah penting untuk membezakan gejala bisa sindrom neurotoksik ini dari pesakit yang kematian otak atau "brain death". Pesakit tidak dapat bertindak balas terhadap kesakitan fizikal kerana lumpuh dan memerlukan ubat pelali yang mencukupi semasa dirawat. Seorang pesakit yang mengalami pengalaman ini juga mungkin akan memerlukan sokongan psikologi setelah pulih dari lumpuh.

**Address for correspondence and reprint requests:** Ahmad Khaldun Ismail. Department of Emergency Medicine, Faculty of Medicine, Universiti Kebangsaan Malaysia Medical Centre, Jalan Yaacob Latif, Bandar Tun Razak, 56000 Cheras, Kuala Lumpur, Malaysia. Tel: +603 91455703 Fax: +60391456577 E-mail: khaldun\_ismail@yahoo.com

**Kata kunci:** kecemasan, bisa, neurotoksik, gigitan ular

## ABSTRACT

The incidence of envenoming from king cobra, *Ophiophagus hannah* in human is relatively rare. Its venom acts on the postsynaptic region of the neuromuscular junction causing descending flaccid paralysis. Locked-in syndrome is a clinical state of inability to provide motor response in a conscious patient. Many reported cases of locked-in syndrome following neurotoxic snake-bite mimics brain death. We report a case of a middle aged man who presented with progressive neurological deficit following a king cobra bite over his right arm. He had local and systemic neurotoxic envenoming. His condition deteriorated, and was intubated and ventilated in the emergency department. He received a total of 33 vials of the *Ophiophagus hannah* monospecific antivenom and subsequently recovered well with no neurological deficit. Retrospectively, he was able to recall the events and while he was lying paralysed and intubated under minimal sedation in the intensive care unit. He described it as a terrifying and painful experience. This case highlights the rare presentation of locked-in syndrome following a systemic envenoming from a king cobra bite. It is important to differentiate neurotoxic snake envenoming lock-in syndrome from brain dead. Patients are unable to respond to physical pain and require adequate analgesia. A patient suffering this highly distressing experience may require psychological support.

**Keywords:** emergency, envenoming, neurotoxicity, snakebite

---

## INTRODUCTION

King cobra, *Ophiophagus hannah* (*O. hannah*) is the largest venomous snake in the world (Figure 1). Envenomation from *O. hannah* is relatively rare and usually involves those handling snakes. A patient bitten by *O. hannah* may manifest local and systemic signs of envenoming. Local tissue necrosis, with or without secondary infection, is a common feature of envenoming from cobra bites (Warrell 2010; Reid et al. 1963). A patient may present with lethargy, nausea, vomiting and in more severe cases, victims may

develop hypotension, tachycardia, altered conscious level, shock and death (Warrell 2010; Reid et al. 1963). Systemic neurotoxic envenoming from *O. hannah* could result in the early onset of ptosis, blurring of vision, paraesthesia, difficulty in speaking, weaknesses of limbs and respiratory failure (Warrell 2010; Reid et al. 1963; Gold et al. 2002). One of the infrequently documented neurological manifestations following cobra bite envenoming is locked-in syndrome (LIS) (Agarwal et al. 2006; Azad et al. 2013). Here, we report a case of LIS following *O. hannah* envenoming.



Figure 1: A) A representative specimen of a king cobra, *Ophiophagus hannah* and its ability to rear up approximately one third of its length. It can grow to more than 5 metres long being the largest venomous snake in the world (photo copyright to Ahmad Khalidun Ismail); B) The typical large 'butterfly' shaped occipital scales on a king cobra's head (photo copyright to Taksa Vasaruchapong)

### CASE REPORT

A 30-year-old gentleman presented to an emergency department (ED) 35 mins following a bite by a four-meter long wild-caught king cobra. According to the patient, he was bitten in the right arm while trying to capture the snake. The bite lasted approximately ten seconds before they managed to release it. The snake was subsequently killed. The patient complained of difficulty opening the eyes, blurred vision, nausea, vomiting and dizziness during transportation to the hospital. On arrival, he had generalised muscle weakness, circumoral paraesthesia, hypersalivation and slurred speech. There was pain and swelling over the entire right forearm extending to the fingers. He was tachycardic, tachypnoeic and unable to speak or swallow. He was intubated and ventilated in the ED. Five vials of the *O. hannah* monospecific antivenom (OHAV) was administered in the ED prior to admission to the Intensive Care Unit (ICU). An additional of 28 vials of OHAV was administered in six

divided doses over the course of 36 hrs in the ICU. The patient only received minimal sedation and analgesia. The first neurological response was noted 28 hrs post incident. The patient was able to grimace and shook his head upon calls. At the 30th hr post incident the patient was able to obey simple commands and opening the eyes slightly. By the 48th hr of admission, the patient was breathing spontaneously, self initiated eye opening and obeying command for muscle movements. In total, 33 vials of OHAV were administered. The patient developed hypotensive episodes while intubated and ventilated in ICU and was administered boluses of intravenous fluids and inotropic support. As a consequence he developed acute kidney injury which resolved with adequate hydration. All vitals eventually returned to normal and the inotrope was stopped. The oedema progressed proximally to involve the chest and supraclavicular region with clear blisters forming over the fingers, forearm and arm (Figure 2a). Multiple enlarged and tender lymph nodes

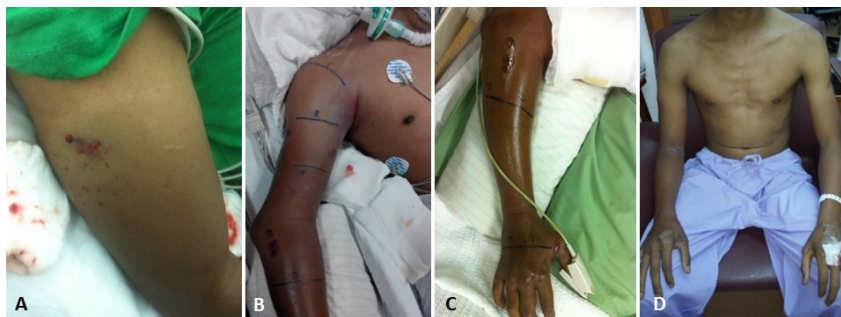


Figure 2: The progression following the king cobra, *Ophiophagus hannah* bite over the right arm. A) The bite marks on the right arm on arrival to the ED; B) Proximally progressing oedema involving the chest and supraclavicular region with ecchymosis in the arm and lymphadenitis in the axilla 12 hrs post incident; C) Formation of serosanguineous blisters over the fingers, hand, forearm and arm 48 hrs post incident D) Significant resolution of oedema and other local signs of envenoming 10 days post incident.

were palpable in the right axilla. The pain score was 5/10 and was controlled with regular intravenous patient controlled analgesia (PCA) Morphine. In view of the possibility of infection that may arise from tissue necrosis, regular intravenous ampicillin/sulbactam was administered. The patient was extubated 49 hrs post admission and was transferred to general medical ward. In view of logistic reason, the patient requested a transfer to another hospital on the fifth day for continuation of care. The oedema, soft tissue inflammation, multiple bullae and ecchymosis at posterior right upper arm resolved over the subsequent five days (Figure 2b). There was an area of fluctuancy at the bite site. Musculoskeletal ultrasound revealed subcutaneous echogenic collection approximately 2.9 cm x 0.7 cm x 2.4 cm at the anterolateral aspect of the arm. In view of the size and normal inflammatory markers, he was treated medically with continuation of the oral antibiotics. In a retrospective interview, the patient was able to recall

the period when he was paralyzed but able to hear the conversations taking place around him. He felt severe pain in the arm and was aware of the procedures performed but unable to response or move. He was able to recall family members visiting him and the conversations between healthcare providers in the ICU. Following significant recovery, he was discharged home on day 12, post incidence (Figure 2c). The patient was reviewed one week later with complete resolution without any adverse sequelae.

## DISCUSSION

Locked-in syndrome can be understood as a state of inability to provide motor response in a conscious patient, and is classified into classic, incomplete and total (Bauer et al. 1979). Classic LIS patient has quadriplegia and anarthria with preservation of consciousness and vertical eye movements. Incomplete LIS presents similarly to the classic LIS with the presence of remnant voluntary movements. Total

LIS presents with total immobility and inability to communicate through vertical eye movements despite full consciousness (Bauer et al. 1979). This clinical phenomenon is commonly encountered in patients who have an acute insult or lesion involving the ventral pons. Common precipitating factors include stroke, encephalitis or trauma (Smith & Delargy 2005). Extensive destruction involving bilateral corticobulbar or the corticospinal tracts in the cerebral peduncles area resulting from either ischemia, haemorrhage, space occupying lesion, demyelinating conditions, metabolic disorder, such as central pontine myelinolysis, may also contribute to this condition (Smith & Delargy 2005).

In this case, the patient was put on a mechanical respiratory support due to respiratory failure with minimal sedation. Following the successful reversal of the paralysis, the patient gave an account of being totally aware of his surrounding but was not able to respond to any stimuli. He was able to recall and describe the chronological events while he was paralysed, including the conversations between family members and medical personnel around him. He described the experience as *“feeling trapped and totally helpless”*. He explains, *“I tried to tell them I was awake and can hear them, but I was powerless. I heard conversations mentioning I was in critical state, my blood pressure was low and other details of my condition. I had to tell myself to stay psychologically strong and the only thing I could do was to pray.”* Patient

concluded that it was a terrifying and painful experience.

*O. hannah* venom consist of complex protein mixtures encoded by several multilocus gene families that function synergistically to cause incapacitation (Danpaiboon et al. 2014). It consists of at least 14 different protein families, including three finger toxins, phospholipases, cysteine-rich secretory proteins, cobra venom factor, muscarinic toxin, L-amino acid oxidase, hypothetical proteins, low cysteine protein, phosphodiesterase, proteases, vespryn toxin, Kunitz/basic pancreatic trypsin inhibitor (BPTI)-type inhibitors, growth factor activators and others (coagulation factor, endonuclease, 5'-nucleotidase) (Danpaiboon et al. 2014; Li et al. 1994). A functional proteomics study of *O. hannah* venom sampled from five distinct geographic regions revealed fast evolution and dynamic translational regulation of the venom composition (Chang et al. 2013). Chinese *O. hannah* venom were found to be more fatal to mice, while the Southeast Asian *O. hannah* were more fatal to lizards. The remarkable variations may reflect the importance of using antivenom raised from indigenous species for snakebite envenoming treatment (Chang et al. 2013).

Circulating venom from *O. hannah* bite acts on the postsynaptic region of neuromuscular junction. This leads to descending paralysis of the voluntary muscles (Warrell 2010). Patient is paralyzed, unable to ventilate spontaneously and unable to communicate verbally thus giving

the impression of a patient in a vegetative state. Many reported cases of LIS secondary to snake bite mimics brain death with GCS of 3/15 with the absence of brain stem reflexes such as fixed dilated pupils and absent doll's eyes reflex (Agarwal et al. 2006; Azad et al. 2013; John et al. 2008; Prakash et al. 2008; Dayal et al. 2014). Clinical assessment aided by confirmatory tests such as cerebral angiography, electroencephalography, transcranial doppler ultrasonography and cerebral scintigraphy would exclude brain dead (Wijdicks 2001). Neurotoxic snake-venom-induced-LIS has been shown resolve following the administration of optimal amount of the appropriate anti-snake venom (ASV).

## CONCLUSION

In addition to differentiating neurotoxic snake envenoming LIS from brain dead in patients, healthcare providers must be aware that patients may be suffering from physical pain that require adequate analgesia. A patient suffering this highly distressing experience may also require psychological support as part of their management regime.

## REFERENCES

- Agarwal, R., Singh, N., Gupta, D. 2006. Is the patient brain-dead? *Emerg Med J* 23(1): e5.
- Azad, C., Mahajan, V., Jat, K.R. 2013. Locked-in syndrome as a presentation of snakebite. *Indian Pediatr* 50(7): 695-7.
- Bauer, G., Gerstenbrand, F., Rimpl, E. 1979. Varieties of the locked-in syndrome. *J Neurology* 221(2): 77-91.
- Chang, H.C., Tsai, T.S., Tsai, I.H. 2013. Functional proteomic approach to discover geographic variations of king cobra venoms from Southeast Asia and China. *J Proteomics* 89:141-53.
- Danpaiboon, W., Reamtong, O., Sookrung, N., Seesuy, W., Sakolvaree, Y., Thanongsaksrikul, J., Dong-din-on, F., Srimanote, P., Thueng-in, K., Chaicumpa, W. 2014. Ophiophagus hannah Venom: Proteome, Components Bound by Naja kaouthia Antivenin and Neutralization by N. kaouthia Neurotoxin-Specific Human ScFv. *Toxins (Basel)* 6(5): 1526-58.
- Dayal, M., Prakash, S., Verma, P.K., Pawar, M. 2014. Neurotoxin envenomation mimicking brain death in a child: A case report and review of literature. *Indian J Anaesth* 58(4): 458-60.
- Gold, B.S., Dart, R.C., Barish, R.A. 2002. Bites of venomous snakes. *N Engl J Med* 347(5):347-56.
- John, J., Gane, B.D., Plakkal, N., Aghoram, R., Sampath, S. 2008. Snake bite mimicking brain death. *Cases J* 1(1): 16.
- Li, Z.Y., Yu, T.F., Lian, E.C. 1994. Purification and characterization of l-amino acid oxidase from king cobra (*Ophiophagus hannah*) venom and its effects on human platelet aggregation. *Toxicon* 32(11): 1349-58.
- Reid, H.A., Thean, P.C., Artin, W.J. 1963. Epidemiology of Snake Bite in North Malaya. *BMJ* 1(5336): 992-7.
- Prakash, S., Mathew, C., Bhagat, S. 2008. Locked-in Syndrome in Snakebite. *J Assoc Physicians India* 56: 121-2.
- Smith, E., Delargy, M. 2005. Locked in syndrome. *BMJ* 330(7488): 406-9.
- Warrell, D.A. 2010. Guidelines for the Management of Snake-Bites. World Health Organization, Regional Office for South-East Asia. [http://apps.searo.who.int/PDS\\_DOCS/B4508.pdf](http://apps.searo.who.int/PDS_DOCS/B4508.pdf) [16 January 2015].
- Wijdicks, E.F. 2001. The diagnosis of brain death. *N Engl J Med* 344(16): 1215-21.

Received: 4 May 2017

Accepted: 6 July 2017