

CASE REPORT

Septic Hip Dislocation with a Preserved Femoral Head: Successful Outcome Following Open Reduction

KAMAL J, ABDUL HALIM AR, SHARAF I

Department of Orthopaedics and Traumatology, Faculty of Medicine, Universiti Kebangsaan Malaysia Medical Centre, Jalan Yaacob Latif, Bandar Tun Razak, 56000 Cheras, Kuala Lumpur, Malaysia.

ABSTRAK

Artritis septik pinggul kanak-kanak adalah kejadian serius yang boleh membawa kesan jangka panjang yang tidak diingini. Bagi neonat, ia mengakibatkan kerosakan pinggul yang teruk terutamanya jika rawatan lambat dimulakan. Antara akibat daripada artritis septik ini termasuk kerosakan struktur dan ketidakstabilan sendi yang boleh menyebabkan dislokasi, seterusnya menjurus kepada kecacatan anggota badan, degenerasi sendi lebih awal dan limitasi pergerakan sendi. Pembedahan pada waktu yang tepat boleh memperbaiki keadaan dan fungsi pinggul. Terdapat segelintir pesakit yang terlibat dengan dislokasi pinggul septic didapati mempunyai kepala femur yang elok, tetapi kumpulan ini tidak dibincangkan di dalam kajian-kajian yang lepas. Baru-baru ini, kumpulan pesakit sebegini dianggap sebagai entiti tersendiri. Laporan ini menerangkan tentang seorang kanak-kanak berumur 2 tahun yang berjaya dirawat selepas dislokasi pinggul septic dan menunjukkan keputusan yang baik 11 tahun kemudiannya.

Kata kunci: artritis septik, dislokasi pinggul, kanak-kanak, jangkitan

ABSTRACT

Septic arthritis of the hip in children represents a serious disorder with unfavourable long-term sequelae. In neonates, a poor hip outcome is expected especially if the treatment was delayed. Late sequelae can lead to structural joint damage and instability, causing deformity and dislocations which ultimately may result in limb length discrepancy, early degenerative changes and limited range of motion. Surgery at the appropriate time can improve the hip condition and functional outcome. Previous classifications of post septic hip sequelae are useful guides for treatment, but did not discuss one particular group of patient. This group-septic

Address for correspondence and reprint requests: Muhammad Kamal Muhammad Abdul Jamil. Department of Orthopaedics and Traumatology, Faculty of Medicine, Universiti Kebangsaan Malaysia Medical Centre, Jalan Yaacob Latif, Bandar Tun Razak, 56000, Cheras, Kuala Lumpur, Malaysia. Tel: +603-91456005 Fax: +603-91456674 E-mail: drkortho@gmail.com

hip dislocation with a preserved femoral head, has recently been described as a distinct entity. This report highlights an 11-year follow-up of a 2-year-old child who had a successful outcome following open reduction and varus derotation osteotomy for a septic hip dislocation with a preserved femoral head.

Keywords: septic arthritis, hip dislocation, child, infection

INTRODUCTION

Late sequelae of hip septic arthritis vary from just minor changes of the hip and acetabulum to marked destruction causing functional impairment. Delayed or missed diagnosis, especially in newborns is one of the major factors for poor outcome but the residual sequelae is quite diverse and unpredictable. Various procedures have been described to overcome residual deformities as a result of septic arthritis of the hip (Dobbs et al. 2003; Choi et al. 2005; Wang et al. 2007), with varied results. Generally, age at presentation and types or severity of the condition determine the choice of management. The more severe the sequelae, the worse prognosis is expected and the more likely salvage or reconstructive surgeries are needed.

Earlier radiographic classifications have been introduced to describe the residual deformities as a result from septic hip and those were useful guides for treatment (Hunka et al. 1982; Choi et al. 1990). However, they were criticized to be too complex and have poor intraobserver agreement (Forlin & Milani 2008). More recently, the sequelae of septic hip has been reclassified based on the presence of the femoral head (Forlin & Milani

2008; Johari et al. 2011). Our report highlights the successful treatment of a child with septic hip dislocation and a preserved femoral head.

CASE REPORT

A 2-year-old girl was referred with a painless limp to our clinic. She had been treated during infancy with left knee septic arthritis in another hospital but the septic arthritis of the right hip was missed. She had a 2 cm limb length discrepancy. Radiographs revealed a right hip dislocation with a preserved femoral head. The left knee showed delayed ossification in the lateral femoral condyle (Figures 1a & b).

Open reduction and varus derotation osteotomy was performed for the septic hip dislocation. The femoral head was flattened medially with erosions of the overlying cartilage (Figure 2). The hip was immobilized in a spica for 2 months. Trochanteric epiphysiodesis was subsequently done at age 7 years to minimise trochanteric overgrowth.

At 11 years follow-up, the femoral head had healed with a coxa breva deformity (Figure 3a). The left lateral femoral condyle also healed with minimal deformity (Figure 3b). The

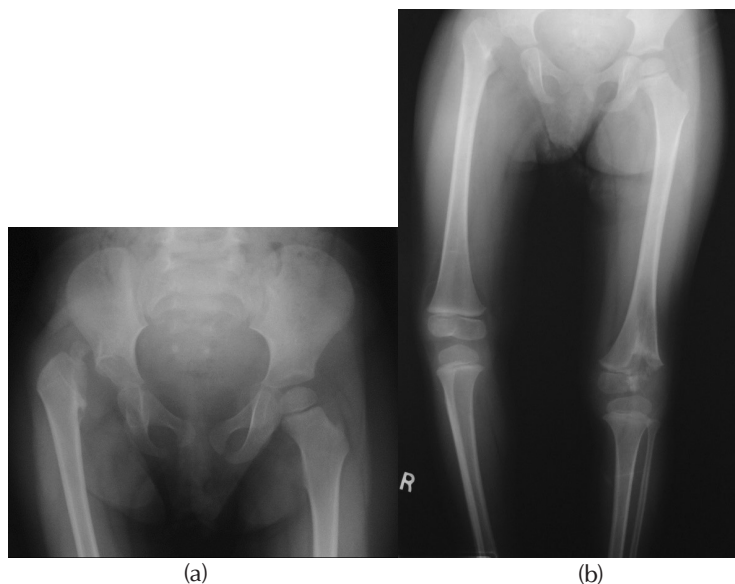


Figure 1: a) Radiograph showing pathological right hip dislocation at the age of 2 years due to a missed septic arthritis during infancy; b) Radiograph at the age of 2 years showing the left distal femoral condyle partially unossified as a result of knee sepsis during infancy.

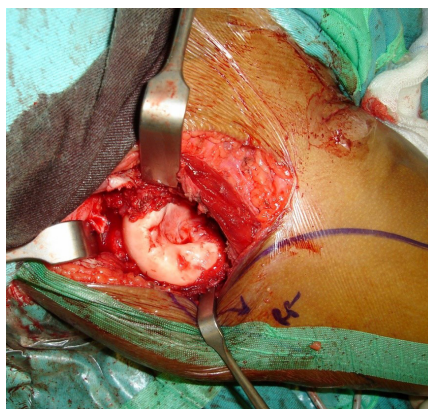


Figure 2: Intraoperative photograph of the deformed right femoral head with erosions of the overlying cartilage.

child at age 13 years remained asymptomatic and had no limitation of daily activities (Figure 3c).

DISCUSSION

Septic arthritis in neonates is uncommon and can be difficult to diagnose compared to older children

(Kabak et al. 2002; Forlin & Milani 2008). This can lead to a delay of treatment which subsequently affects the growth of the femoral head and proximal femur. A child is at risk of a poorer prognosis especially with sepsis during early infancy and with a delay in initial therapy. Kabak et al. (2002) followed up 14 neonates treated for

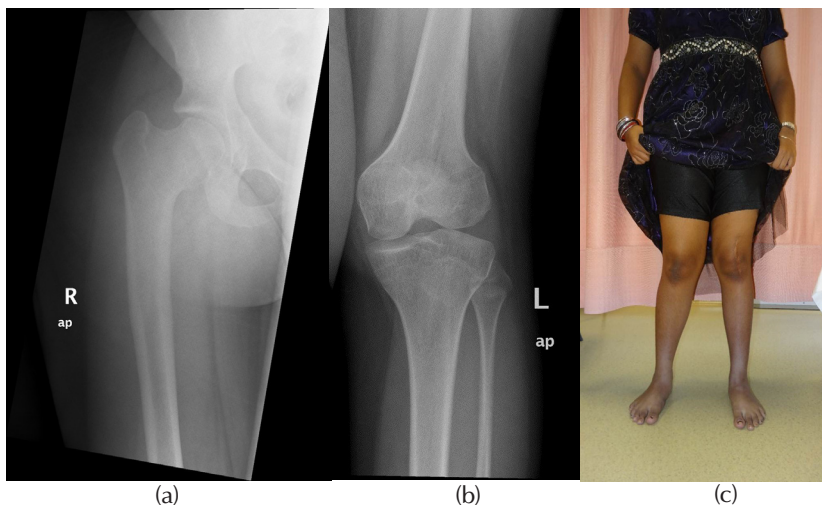


Figure 3: a) Radiograph of the hip after 11 years. The right femoral head healed with a coxa breva deformity; b) Radiograph showing the left knee femoral condyle had healed with minimal deformity after 11 years; c) Photograph of the asymptomatic child at the age of 13 years.

septic arthritis of various joints for at least 2 years and found 12 of them had no severe sequelae. The other 2 patients (1 death and 1 unfavourable hip outcome) were related to late diagnosis and therapy.

Once the patient developed a severe sequelae, it is a challenge for the surgeon to improve the damaged hip. This would be a temporary measure to produce the optimum function and delay the definitive surgery which may be needed in adulthood. The first classification to describe these residual deformity of septic hips in children has 5 types and 4 subtypes, from minimal to increasing severity (Hunka et al. 1982). Type V being the most severe is when the hip is dislocated with completely destroyed femoral head. Hunka et al. (1982) performed trochanteric arthroplasty in 5 of his patients with type V hips which showed satisfactory outcome in 3 of them. They also advocated the criteria for satisfactory

hip outcome which include a stable joint, arc of flexion $>50^{\circ}$ and pain-free hip that allows usual daily activities.

Choi et al. (1990) modified Hunka classification into 8 subtypes which gives a more comprehensive guideline. The author also retrospectively reviewed 43 patients which were operated with various reconstructive and salvage surgeries and devised a treatment algorithm for severe sequelae of infantile septic arthritis of the hip. Although the classification was very detailed, it is complex and can be difficult to apply. Both Hunka and Choi did not emphasize the significance of the femoral head.

Other studies regarding surgical treatment of septic hip sequelae were focused on the most severe type, where the femoral head was absent. Dobbs et al. (2003) evaluated their own patients with Hunka type V hips which were treated with trochanteric arthroplasty and proximal varus osteotomy

(Dobbs et al. 2003). At a mean of 15-year follow-up, they reported satisfactory outcome in 5 patients and recommended staged procedure to reduce the risk of avascular necrosis. Another study reviewed 30 hips with Hunka type V treated with trochanteric arthroplasty (Wang et al. 2007). They recommended a single stage procedure as early as one year of age. This includes resecting any remnant of femoral head or neck, before the proximal femur is reshaped to replace the head.

Recently, the sequelae of septic hip have been reclassified based on presence of the femoral head. Septic hips with femoral head present are classified as a separate entity (Forlin & Milani 2008; Johari et al. 2011). Forlin and Milani (2008) treated 3 dislocated hips with femoral head present. They chose early reconstruction procedures and believed it produced better results. These included open reduction, proximal varus osteotomy and Dega acetabuloplasty.

Johari et al. (2011) further discussed this specific group in detail, and presented the outcome of 21 hips (Johari et al. 2011). They performed closed reduction in young patients and had a 35% success rate. For patients treated with open reduction, supplementary procedures were done when indicated. Femoral shortening for high dislocation, acetabular procedures for dysplasia, and femoral derotation osteotomy for ante version were performed on 14 hips. Nine out of 18 patients had good clinical results, with the longest follow up at 16 years of age. The importance of recognizing

the absence of femoral head was highlighted in this case series. In cases that the femoral head had avascular necrosis or absent were associated with poor results. Other factors that also led to poor outcome include hip stiffness and premature fusion of the triradiate cartilage.

Our patient was operated on at the age of two years. Open reduction with varus derotation osteotomy of the femur was done to ensure concentric reduction. We retained the remnant of the femoral head even though it was deformed. We were able to avoid any salvage or complex reconstructive procedures as the right femoral head and the left distal femoral condyle both healed with minimal residual deformities. We concur with the previous authors (Johari et al. 2011; Forlin & Milani 2008) that when the femoral head is present after septic hip dislocations, the outcome is favourable after reduction.

CONCLUSION

Children have enormous capability of bone remodeling. We have shown that even with a deformed femoral head initially, our patient had a good hip outcome following open reduction and femoral varus osteotomy. When femoral head is present after septic hip dislocation, complex surgeries are unnecessary and parents can be informed of a better prognosis for their children.

REFERENCES

- Choi, I.H., Pizzutillo, P.D., Bowen J.R., Dragann, R., Malhis, T. 1990. Sequelae and reconstruction

- after septic arthritis of the hip in infants. *J Bone Joint Surg Am* 72(8): 1150-65.
- Choi, I.H., Shin, Y.W., Chung, C.Y., Cho, T.J., Yoo, W.J., Lee, D.Y. 2005. Surgical Treatment of the Severe Sequelae of Infantile Septic Arthritis of the Hip. *Clin Orthop Relat Res* (434): 102-9.
- Dobbs, M.B., Sheridan, J.J., Gordon, J.E., Corley, C.L., Szymanski, D.A., Schoenecker, P.L. 2003. Septic Arthritis of the Hip in Infancy: Long-Term Follow-Up. *J Pediatr Orthop* 23(2): 162-8.
- Forlin, E., Milani, C. 2008. Sequelae of Septic Arthritis of the Hip in Children: A New Classification and a Review of 41 Hips. *J Pediatr Orthop* 28(5): 524-8.
- Hunka, L., Said, S.E., MacKenzie, D.A., Rogala, E.J., Cruess, R.L. 1982. Classification and surgical management of the severe sequelae of septic hips in children. *Clin Orthop Relat Res* (171): 30-6.
- Johari, A.N., Dhawale, A.A., Johari, R.A. 2011. Management of post septic hip dislocations when the capital femoral epiphysis is present. *J Pediatr Orthop B* 20(6): 413-21.
- Kabak, S., Halici, M., Akcokus, M., Cetin, N., Narin, N. 2002. Septic arthritis in patients followed-up in neonatal intensive care unit. *Pediatr Int* 44(6): 652-7.
- Wang, E.B., Ji, S.J., Zhao, Q., Zhang, L.J. 2007. Treatment of severe sequelae of infantile hip sepsis with trochanteric arthroplasty. *J Pediatr Orthop* 27(2): 165-70.

Received: 19 January 2017

Accepted: 24 August 2017